

Research

Open Access

Percutaneous closure of interatrial communications in adults – prospective embolism prevention study with two- and three-dimensional echocardiography

Fabian Knebel, Volker Glicch, Torsten Walde, Alexander Panda, Wassem Sanad, Stephan Eddicks, Gert Baumann and Adrian C Borges*

Address: Medical Clinic for Cardiology, Angiology, Pulmology, Charité Campus Mitte, Berlin, Germany

Email: Fabian Knebel - fabian.knebel@charite.de; Volker Glicch - volker.glicch@charite.de; Torsten Walde - t.walde@gmx.de; Alexander Panda - alexpanda@web.de; Wassem Sanad - wassem.sanad@charite.de; Stephan Eddicks - stephan.eddicks@charite.de; Gert Baumann - gert.baumann@charite.de; Adrian C Borges* - adrian.borges@charite.de

* Corresponding author

Published: 19 May 2004

Received: 31 March 2004

Cardiovascular Ultrasound 2004, **2**:5

Accepted: 19 May 2004

This article is available from: <http://www.cardiovascularultrasound.com/content/2/1/5>

© 2004 Knebel et al; licensee BioMed Central Ltd. This is an Open Access article: verbatim copying and redistribution of this article are permitted in all media for any purpose, provided this notice is preserved along with the article's original URL.

Abstract

Background: Patients with interatrial communications after paradoxical embolic events are at risk for recurrent thromboembolism. We hypothesized that transcatheter closure of the defects would result in long-term prevention of systemic embolism and performed clinical and echocardiographic follow-up.

Methods: We included 161 patients (mean age 46.8 ± 11 years, 83 females) with patent foramen ovale or atrial septal defect and at least one documented paradoxical systemic thromboembolic event and/or a large atrial shunting.

Results: The implantation procedure was successfully performed without major complications in all patients and minor complications in 2.5%. Two and / or three dimensional echocardiography was performed before and after 4 weeks and 12 months using a multiplane transoesophageal probe. After 4 weeks and 6 months two patients had minimal shunting. These residual defects were closed with a second device implantation without shunting after further 4 weeks. During a follow-up of 324.3 patient years (range, 13 to 19 months), recurrent embolic events occurred in only 1 patient (0.6%).

Conclusion: After primary paradoxical systemic embolism, results of transcatheter occlusion of the interatrial communications are dependent on the closure device system and can prevent further secondary embolic events for up to 1 year after the percutaneous closure. Three dimensional echocardiography provides dynamic features of the defects and the post closure status and may lead to an improved understanding and diagnosis of the interatrial defect.

Introduction

Atrial septal defect (ASD) and patent foramen ovale (PFO) are the most common cardiac abnormalities. They predispose to cerebral ischemia as a result of paradoxical

thromboembolism by right-to-left shunting under conditions or physiologic maneuvers that raise right atrial pressure [1,2]. Several studies using contrast echocardiography established a strong association

between cryptogenic stroke and the presence of PFO in young adults < 55 years old [1,3,4]. Stroke databases suggest that despite intensive evaluation, approximately 40% of all patients suffering ischemic strokes without a clearly identifiable cause [5]. The term "presumed paradoxical embolism" is used for patients after exclusion of all known causes of arterial thrombosis and thromboembolism (atherosclerosis, atrial arrhythmia). There is a strong correlation between PFO and primary occurrences of strokes [6]. The risk of recurrent cerebrovascular events is increased in patients with PFO combined with atrial septum aneurysm [7]. Patients with interatrial communications and paradoxical embolism are also at increased risk for recurrent thromboembolic cerebral events in up to 3.8% per year [8].

An optimal secondary stroke prevention strategy in patients with ASD and/or PFO is not clearly defined [9]. Percutaneous closure of the interatrial communication, surgical closure of the defects, or oral anticoagulation in patients with small defects (with only small shunt volume) are alternatives for secondary prevention of recurrent thromboembolic events. There is an increased risk for subsequent ischemic cerebral events despite anticoagulant therapy if an interatrial communication was diagnosed by transesophageal contrast echocardiography [10], thus demonstrating the need for alternative therapies. Surgical ASD or PFO closure has been proven feasible, but includes thoracotomy and heart-lung machine. The results have been mixed with respect to stroke prevention [11]. Therefore, different devices for nonsurgical, transcatheter defect closure have been developed recently [12,13].

The selection of patients for transcatheter closure of atrial septal defects requires accurate information regarding the anatomy, size and topography of the defect.

Percutaneous defect closure is possible with a variety of different devices. In the USA, PFOs may be closed percutaneously under the Food and Drug Administration mandated humanitarian device exemption (HDE) guidelines in limited specific circumstances, both with CardioSEAL and the Amplatzer PFO Occluder. Assessing the efficacy of percutaneous closure for each device has been troublesome for different reasons: the case series nature of existing studies, lack of randomised trials, as well as a lack of defined and clinically meaningful end points. The early experiences with the Clamshell device resulted in 4 recurrent TIA after 24 months in 28 patients [14]. In a multi-centre trial using the ASDOS device, recurrent TIA occurred in only 1 of 46 patients with PFO with a high rate of peri- and postprocedural complications [15]. Transesophageal echocardiography is the preferred method for pre-procedural and follow-up examination. Three-dimensional (3D) echocardiography is a new diagnostic tech-

nique to obtain additional anatomic details of ASD in vivo and, thus, predict the procedural success of ASD closure and detect post procedural complications.

Placement of a device does not mean that all antithrombotic agents can be halted [5]. No benefit-risk ratio for transcatheter closure has been established yet. So far descriptive series have been followed only by additional case-control studies, without the prospective collection of primary occurrences of cryptogenic strokes and PFOs [16,17].

Choice, duration, and benefit and risks of peri- and post-implant antiplatelet or anticoagulant therapy remains unclear and undefined. A combination of aspirin and clopidogrel for 6 months according to the post-coronary stent implantation regime was used in most patients. Systematic reviews could demonstrate that percutaneous PFO closure has a protective effect on stroke and TIA recurrence compared with medical treatment: after the first year, for 23 patients one stroke or TIA was prevented compared to medical treatment alone [18].

However, given a high procedural success rate and a low number of residual shunts in the present study and in the study by Bruch et al. [19], the percutaneous closure of interatrial defects may become the favourable method after paradoxical embolism.

There are considerable differences between studies regarding surgical closure of defects with a recurrence rate of stroke or TIA between 7.5% after 12 months [20] and 19.5% within 13 months [21]. The different surgical techniques and patient selection criteria may explain this wide range of embolism recurrence.

Throughout the past decade, a number of randomized controlled trials including the percutaneous closure trial and the Paradoxical Embolism Prevention Study in Ischemic Stroke (PEPSIS) trial were attempted but have failed. New trials are currently performed, and will likely contribute to answer the necessary scientific and clinical questions to allow for improved patient care. CLOSURE-1, is a trial with more than 1600 patients which tests the superiority of the CardioSEAL-STARFlex versus the best medical treatment, evaluating neurologic end points. A second trial, RESPECT, evaluates the equivalency of Amplatzer PFO Occluder with clinician-determined best medical therapy in patients after stroke.

Adams [22] concluded that none of the therapeutic options could be recommended if the rules of evidence are used to assess the current data. This study prospectively assesses the success rate, the risk for recurrent cerebrovascular events, and the diagnostic value of two-

Table 1: Patient and Clinical Characteristics

Total	161
Female sex [no]	83
Age [years]	
• Mean \pm SD	46.8 \pm 11
• Range	19–78
Atrial septal anatomy	
• PFO only	79
• PFO and ASA	35
• ASD only	34
• ASD and ASA	13
PFO-size [mm]	
• Mean \pm SD	11 \pm 5
• Range	5–14
ASD-size [mm]	
• Mean \pm SD	13 \pm 6
• Range	6–26
Thromboembolic index event before – n (%)	144 (89)
• CVA	77 (48)
• TIA	62 (38)
• Peripheral embolism	5 (3)
Follow-up period [months]	
• Mean \pm SD	17 \pm 11
• Range	13–19

PFO = patent foramen ovale; ASD = atrial septal defect; CVA = cerebrovascular accident; TIA = transient ischemic attack; ASA = atrial septal aneurysm

dimensional and three-dimensional transesophageal echocardiography before and after percutaneous, transcatheter closure of interatrial communications with a variety of devices in consecutive patients after paradoxical cerebrovascular events.

Methods

Patient population

Between May 1993 and December 2002, percutaneous closure of interatrial communications was performed at our institution in 161 patients with a PFO or ASD (mean age 46.8 \pm 12.9 years; range 19 to 78 years) and \geq 1 documented thromboembolic events or a pulmonary-to-systemic flow ratio by oximetry (Fick method) of at least 1.5:1 and/or symptoms of right-sided volume overload. The patients were referred from stroke units. A thromboembolic event was considered to be due to paradoxical embolism if the following criteria were met: (1) presence of PFO (with or without septal aneurysm) or ASD with spontaneous or provokable right-to-left shunt during contrast transesophageal echocardiography, (2) clinically and neurologically confirmed ischemic stroke or symptoms of transient ischemic attack with neuroradiologically identified intracranial ischemic or clinically and radiologically verified extracranial peripheral thromboembolism; and (3) exclusion of any identifiable cause for the thromboembolic event other than the interatrial communica-

tion (Table 1). All patients gave written informed consent before the implantation procedure.

Echocardiographic evaluation

Each patient underwent transthoracic and multiplane transesophageal echocardiographic examination. For pre-interventional diagnosis, peri-interventional guidance, and post-interventional follow-up, an HP SONOS 5500 (Hewlett-Packard, USA) echocardiography system with a S4 transducer using the harmonic mode (transmitting frequency of 2.1 MHz and a receiving frequency of 4.2 MHz), and the 5 MHz multiplane transoesophageal probe, or the VIVID FIVE system (General Electric-Vingmed Ultrasound, Horton, Norway) with a 5 MHz multiplane transesophageal probe were used. The transthoracic studies were performed in left lateral recumbent position with non-contrast second harmonic imaging (Octave mode: transmit frequency of 1.7–1.9 MHz and a receive frequency of 3.4–3.8 MHz). Images were obtained using a 2.5-MHz phased array transducer at a depth of 12–16 cm in all standard apical and parasternal views. The contrast agent used during transesophageal echocardiography was Echovist® (Schering AG Berlin, Germany) in order to detect right-to-left shunt at rest and after Valsalva maneuver.

In addition to standard transthoracic imaging and multiplane 2D transesophageal echocardiography, 3D

transesophageal echocardiography was performed to visualize the interatrial septum in patients with ASD since November 2001 ($n = 16$). We used the VIVID FIVE system (General Electric-Vingmed Ultrasound, Horton, Norway), which has the capability for acquisition of serial cross sectional echocardiographic images by a 5-MHz multiplane transesophageal probe. The system was connected with EchoPac (Compac-PC, Windows 2000) for off-line analysis and 3D reconstruction, using the Echo-Pac-3D for Windows software (version 1.02). Serial cross sectional images with increments of 2° were acquired with cardiac and respiratory cycle gating. Cardiac cross-sections were

formatted in their correct sequence according to their electrocardiogram and respiratory phase in cubic data sets. The image data were converted from polar to Cartesian coordinate format and interpolated to "fill the gaps" between sequential cross-sections.

Image display

The interatrial septum was imaged from different computer-generated views, that allowed for identification of the shape, size, rim and cardiac cycle dependent shape changes (Fig. 1).

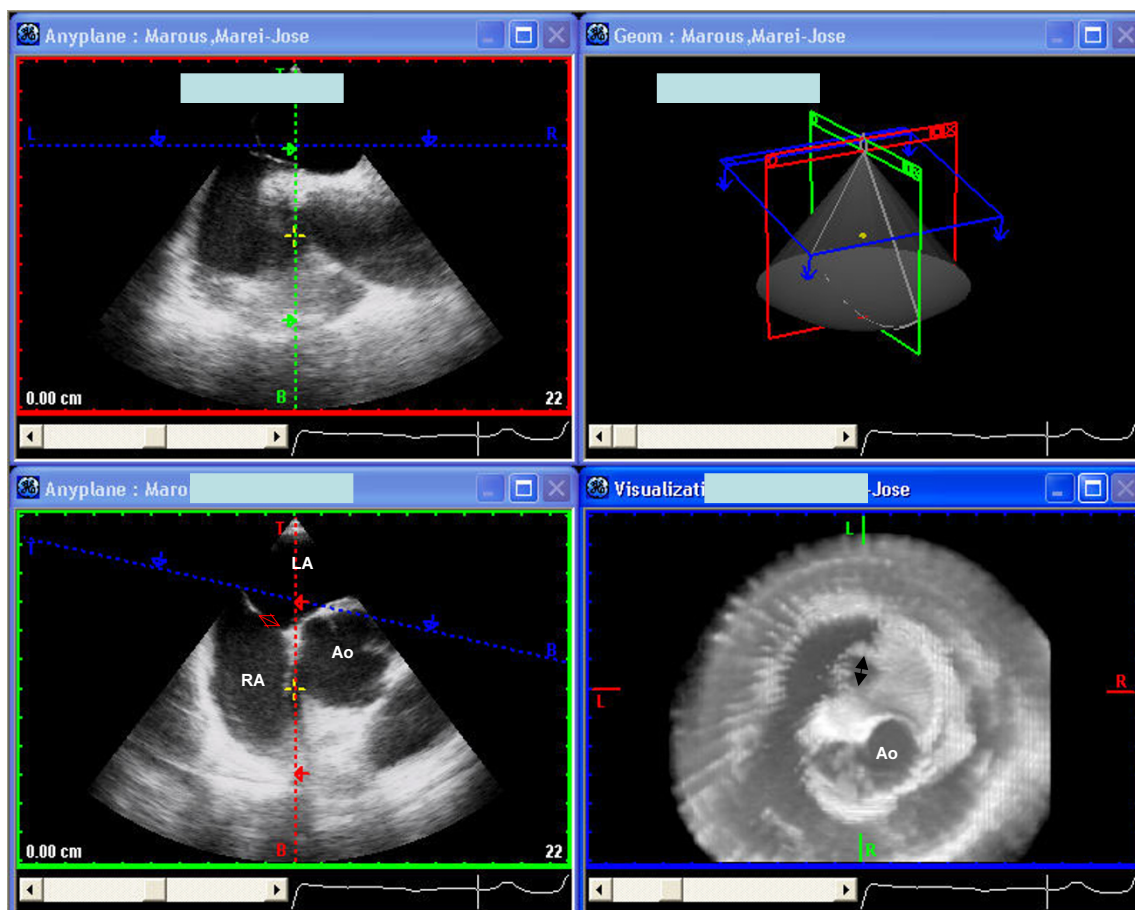


Figure 1

Computer reconstructed two-dimensional images of a large secundum atrial septal defect (upper panels and left lower panel) and 3D echocardiographic reconstruction (right lower panel). LA, left atrium; RA, right atrium.

Volume-rendered display

Once an appropriate cut plane had been chosen, a threshold value was selected to differentiate cardiac structure from the blood pool and background, and a gradient shading algorithm enhanced the views.

Image analysis

From dynamic, volume rendered images looking at the defect from the left and right atrium, specific frames with axis corrected visualization of the defect were defined, and areas were calculated by direct drawing. The echocardiograms were analyzed by two experienced observers.

Implantation procedure

Venous access was gained via the right femoral vein, and the interatrial communication was passed under fluoroscopic guidance with a 7F multipurpose catheter. In all patients, stretch size of the PFO or ASD was determined with an NMT (NMT Medical Corp.) sizing balloon or Equalizer Ballon Catheter 7F (Boston Scientific MEDITECH, Natick, MA, USA). The multipurpose catheter was exchanged for a 7F to 11F transseptal sheath via a standard 0.035-in exchange wire for Cardioseal or Rashkind device implantation, 7F or 8F for other devices. The occluder was delivered through the transseptal sheath and placed within the PFO or ASD without puncture of the interatrial wall under fluoroscopic guidance according to the device-specific implantation recommendations. The occluder was advanced through the sheath into the left atrium until the left atrial part of the device was unfolded. The whole unit was withdrawn under fluoroscopic and /or echocardiographic guidance against the interatrial septum, the right atrial part of the device was unfolded after contrast angiography in order to check the correct position. Before the release of the occluder, the device position was checked again by right atrial contrast angiography in order to delineate the atrial septum. Transesophageal echocardiographic monitoring was performed in all patients with large ASD. At the end of the procedure, the transseptal sheath was removed, and hemostasis was achieved by manual compression.

Out of 43 patients receiving Rashkind devices, 27 patients received anticoagulation initially with heparin and overlapping with phenprocumon until the target INR between 2.5 and 3.0 was reached and oral anticoagulation was continued for 3 to 6 months. All other patients were treated with aspirin 100 mg once daily and Clopidogrel bisulfate 75 mg once daily for 3 to 6 months. All patients received antibiotic prophylaxis (Flucloxacillin 2 g IV) during the procedure.

Follow-up evaluation

Follow-up visits after 6 weeks, and 6 and 12 months included ECG, transthoracic echocardiography. Trans-

esophageal echocardiography with intravenous contrast and fluoroscopic contrast were performed after 6 weeks and 12 months. Any recurrent thromboembolic events were considered as primary end points of the study. Patients with suspected thromboembolic recurrence were re-examined by a neurologist, and whenever possible, an imaging study (MRI or CT) was repeated.

Definitions

Atrial septal aneurysm was defined with an excursion of > 10 mm of the interatrial septum. A PFO was defined as the appearance of microbubbles across the interatrial septum (spontaneous or with Valsalva maneuver) and the absence of a left-to-right shunt with color Doppler technique. An ASD was defined as a left-to-right shunt in the color Doppler in addition to the right-to-left shunt during contrast application.

Procedural complications were defined as any adverse event that occurred within 24 hours of device implantation. The dose area product of radiation was expressed as multiples standard for 2-plane of chest x-rays (1.2 Gy · cm²) according to the German Bundesamt für Strahlenschutz <http://www.bfs.de>.

Statistical analysis

Values are expressed as mean ± standard deviation (SD) unless indicated otherwise. Subgroups were compared by parametric or non-parametric tests (t-tests and Wilcoxon-Mann-Whitney tests, resp.). More than 2 groups were analysed using ANOVA (symmetrically distributed observations) or Kruskal-Wallis test (otherwise). Post-hoc tests were performed (if significant differences proved to be global) with the help of multiple tests or pair-wise comparisons (with the same error of the 1st kind in 3 groups – closed test procedure). Statistical significance was assumed at a value of P < 0.05.

Results

Patient demographics are summarized in Table 1.

Radiation exposure

The mean area dose product per patient for the implantation of the devices was 150,3 Gy cm⁻² (SD 77.6; range: 29 – 441 Gy cm⁻²) and 4.0 Gy cm⁻² for follow-up after 6 weeks and 12 months. The mean fluoroscopy time for the implantation of the devices was 18.5 min (± 6.3; range 5 – 44 min). The multiples of chest x-ray were 125.2 (mean ± 64.6, range 24.2 – 367.5).

Procedural success, complications and follow-up

The implantation was technically successful in all of the 161 patients (100%). There were 3 procedural complications (1.8%), which are summarized in Table 2. During a follow-up of 324.3 patient years (range, 14 to 28

Table 2: Complications, residual shunts and recurrence of embolism

	Total	Procedural complications	Late complications	Residual shunt (after 6 months)	Recurrence of embolism
Amplatzer PFO Occluder	59	1			
Amplatzer Septal Occluder	8				
CardioSEAL Septal Occluder	33	1			1
CardioSEAL Occluder Starflex	11		2	1	
Rashkind	43	1		1	
ASDOS	7		4		
	161	3	6	2	1

months), recurrent embolic events occurred in only 1 patient (0.6%). In one patient the device was surgically removed because of device thrombosis without embolism. The follow-up time free of severe complications (device thrombosis, malfunction, device explantation) is described in (Figure 5). The ASDOS device had a significantly higher complication rate than all other devices. The complication rate of the Amplatzer, Rashkind and Cardioseal devices did not differ significantly during follow-up.

RASHKIND device

Out of 43 patients there was only one procedural complication with too early disconnection of the device, but it could be removed transvasally. Subsequently, another device was successfully implanted, and there were no complications during the follow-up period (at least 12 months). A residual shunt was seen in one patient.

ASDOS (Atrial-Septal-Defect-Occlusion-System); (Sulzer Osypka, Rheinfelden, Germany)

Late complications occurred in 4 of 7 patients: pericardial perforation of the device (n = 1); disconnection of the device (n = 1); thrombosis on the left atrial part despite anticoagulation with an INR between 2.5–3.0 (n = 1); dislocation of the left atrial part (n = 1). Therefore, all remaining ASDOS devices were surgically removed prophylactically and the defect was surgically closed. The further use of this device was stopped [37].

CardioSEAL™ Septal Occluder Implant (Nitinol Medical Technologies, Inc. Mass. USA)

In one patient, a tachyarrhythmia occurred during implantation. In 3 of 33 patients atrial fibrillation were observed during late follow-up, which could be converted into sinus rhythm with medical treatment in two patients and with electrical cardioversion in one patient. In another patient, a cerebrovascular embolism (with TIA) occurred during follow-up due to a large thrombus on the left atrial side of the device despite anticoagulation with target INR

between 2.5–3.0, the device was surgically removed and the defect was closed.

CardioSEAL™ Occluder Starflex (Nitinol Medical Technologies, Inc. Mass. USA)

In 2 patients of 11 patients, 6 weeks after device implantation transesophageal echocardiography detected a large left atrial thrombus, which was surgically removed and the intra-atrial defect was closed.

Amplatzer Septal Occluder and Amplatzer PFO Occluder (AGA Medical Corporation, Golden Valley; MN. USA)

In one patient with Amplatzer PFO Occluder, an air embolism without stroke occurred in one patient. There was no complication during late follow-up in all 8 + 59 patients.

Echocardiographic findings

Color Doppler and contrast transesophageal echocardiography demonstrated complete occlusion in 159 of 161 patients after 1 month. In two patients who had ASD closure, an interatrial contrast passage was demonstrated during a Valsava maneuver after 6 months. Therefore a second occluder device was additionally implanted without complications (patient 1: additional to Cardioseal Starflex: Amplatzer PFO Occluder; patient 2: additional to Rashkind device: Cardioseal Septal Occluder), and without residual right-to-left shunt 4 weeks after the procedure.

Three dimensional echocardiography was performed and was sufficient for analysis of interatrial defects in 26 of 27 patients before and after device implantation (all with ASD) and in additional 21 of 23 patients after closure of the PFO. Three dimensional imaging allowed the visualisation of the device surfaces from both sides, the area calculation of the defects and the visualisation in all image planes and angles (Fig. 1), which was not possible with two-dimensional echocardiography. The mean additional acquisition time for 3D echocardiography is 7 min

(± 3 min) and the mean off-line reconstruction time is 14 min (± 10 min). Intra-observer variability for 3D measurements was 3%, the absolute mean difference was 0.6 mm for ASD maximal diameter. Inter-observer variability for 3D echocardiographic measurements was 5%; the absolute mean difference was 0.4 mm for ASD maximal diameter.

The area of the defects changed significantly during the cardiac cycle from 112 ± 54 mm² to 46 ± 26 mm² ($P < 0.001$). The percentage change ranged from 22.1% to 74.6%, with a mean of 51.2%. The measurement of the length of the anterior rim was only possible with 3D echocardiography: with change during the cardiac cycle from 34 ± 17 mm to 13 ± 7 mm, the percentage change of the distance ranged from 25.3% to 80.6%, mean 65.4%. There was no correlation between percentage change in the defect areas measured by two- and three-dimensional echocardiography ($R^2 = 0.132$).

Discussion

In this article, we present our experience with percutaneous transcatheter closure of an interatrial communication using different septal occluder systems in adult patients.

Device type – complications

The success rate strongly depends on the type of occluder system. Complete PFO closure at follow up can be expected in 90–95% of patients utilising CardioSeal or Amplatzer occluder [5]. There are continuous databases which report an annual recurrent combined stroke/TIA event rate of less than 4% for the CardioSeal [23]. In contrast to these data, we demonstrated the best results with the Amplatzer and Rashkind devices.

The complications in our patient population mainly occurred in those patients, which have received the ASDOS occluder device. Complications in ASDOS-patients were reported previously [24]. For all other devices, the implantation has a low risk-benefit ratio (lowest for Amplatzer and Rashkind) and the complication rate during follow-up was low.

Radiation exposure

Interventional fluoroscopic procedures produce the highest radiation doses of all medical imaging procedures and add to the lifetime risk of fatal cancer [25,26]. The fluoroscopy time and dose-area-product for the implantation of the intra-atrial devices has a high variation in our patient population. Increasing routine and experience in the implantation procedures will hopefully reduce the radiation doses. New techniques, including on-line 3D echocardiography, intracardiac echocardiography) might reduce radiation time in the future. Intracardiac echocardiography might even further reduce fluoroscopy time

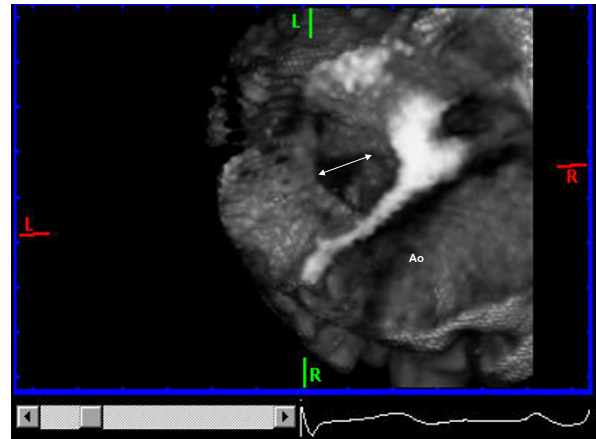


Figure 2

3D transesophageal image of a large secundum atrial septal defect, the image shows the defect area from the left atrium; Ao, ascending aorta.

[27]. Furthermore, studies addressing device implantation in adults by echocardiographic guidance alone without fluoroscopy are currently performed [28].

2D and 3D echocardiography

3D echocardiography provides morphological details in different clinical entities *in vivo* in the quality of an intra-operative or pathologic examination [21].

3D echocardiography allows unique en face views of the atrial septum (Fig. 1) and the closure devices (Fig. 2), and has the ability to measure the maximal diameter and the systolic and diastolic areas of the defect [30,31]. This is a clear advantage of 3D echocardiography, because 2D echocardiography can not display the diastolic-systolic difference of the intraatrial defect area.

3D echocardiography demonstrated the great variability of the shape of the ASD as described before [30,32]. This variability might alter the accuracy of diameter and area calculation by 2D echocardiography and the measurement of the rim by 2D echo. In patients with complex or elongated shapes of the ASD, 2D echo will underestimate the defect maximal diameter. The ASD area changed significantly during the cardiac cycle, with a maximum size in late ventricular systole and a minimum size in late ventricular diastole [30-32]. Changes in defect areas were quite variable among different patients. This variable change has important consequences for the different methods of treatments, i.e. suitability of transcatheter closure devices. As previously described [32] we could also

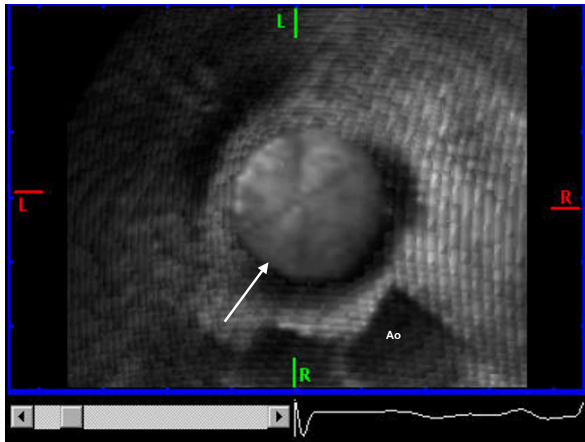


Figure 3
3D transesophageal image of the Amplatzer PFO Occluder (arrow), the image shows the surface of the left atrial part of the device.




Figure 4
Original percutaneous PFO occlusion device: Amplatzer PFO Occluder (AGA Medical, Golden Valley, Minnesota, USA), view of the left atrial surface.

demonstrate, that the changes in defect area were not only parallel to the heart axis from the base to the apex, but also perpendicular to the axis. All defect areas changed symmetrically and concentrically with a similar shape.

Neither the age of the patient, the size of the defect, the heart rate, nor the amount of volume overload affected the extent of contraction [32], although other groups demonstrated reduced contraction in older patients [33].

The degree of contraction cannot be measured accurately with two dimensional echocardiography [32]. For the estimation of dynamic changes in the defect area, 3D echo has additional properties that are lacking with conventional 2D echocardiography: 3D echo provides the angle of the defect axis, and allows cross sectional imaging in any plane.

A better understanding of the dynamic nature of the defects using three dimensional echocardiography may improve the closure rates and may overcome the problems of deployment, residual leaks and the long term cure rates [28].

Closure of a large ASD that extends into the inferior sinus venosus and has no posteroinferior rim is problematic using occluder devices. A large ASD with an absent anterosuperior rim can be closed, but requires special techniques and exact information about extent and location of the rim. 3D echocardiography is the ideal technique to

provide this information, whereas 2 D echocardiography requires the mental reconstruction into 3D information.

The relatively short acquisition and off-line reconstruction times for 3D echocardiography adds to its clinical usefulness.

Other authors have found 3D echo useful in different clinical settings [34-37]. New transthoracic techniques with on-line reconstruction systems and off-line quantification will further improve its clinical usefulness.

Limitations

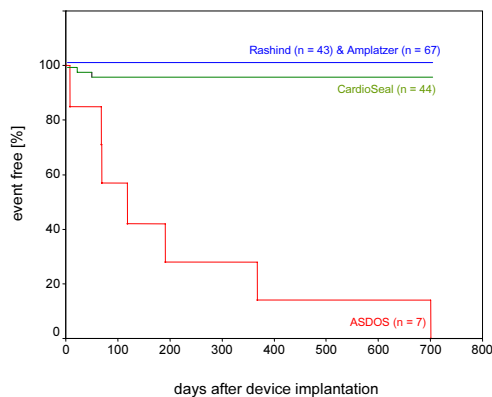
The 3D datasets we used always contained motion artefacts, as the serial cross sectional echocardiographic data are acquired during different times of the cardiac cycle.

Conclusions

Percutaneous closure of interatrial communications appears to be a promising technique in the secondary prevention of recurrent systemic thromboembolic events in patients with ASD and PFO. Two dimensional and three dimensional transesophageal echocardiography is feasible and useful in the pre- and postprocedural diagnosis. Three dimensional echocardiography provided new information on the dynamic nature of secundum atrial septal defects. The amount of contraction had a strong individual variability.

Table 3: Advantages of 3D echocardiography over 2D echocardiography

	2D	3D
Calculation of the defect area	-	+
En face view of the defect	-	+
Measurement of the defect area	+	+
Diastolic – systolic area difference	-	+
Rim calculation	+/-	-
Visualization of shape of defect	-	+

**Figure 5**

In the future, better detection of defect borders using real time three dimensional echo may overcome the problems related to direct measurement.

Prospective studies comparing percutaneous closure of ASD and PFO with antithrombotic and anticoagulation medications will define its future therapeutic value.

Competing interests

None declared.

Authors' contributions

ACB and FK carried out the 2D and 3D echocardiographic studies, participated in the sequence alignment and drafted the manuscript.

VG and ACB performed the invasive and hemodynamic assessment and the device implantation and carried out the follow-up assessment.

AP participated in the sequence alignment and participated in the sequence alignment and drafted the manuscript.

SE and WS participated in echocardiographic assessment of the study and in its design and coordination.

TW and GB participated in the design of the study and performed the statistical analysis, conceived of the study, and participated in its design and coordination.

All authors read and approved the final manuscript.

Note

Table 4: Kaplan-Meier analysis of event-free follow up the different devices (severe complications and device explanation). See figure 5

References

1. Lechat P, Mas JL, Lascault G, Loron P, Theard M, Klimczac M, Drobinski G, Thomas D, Grosgeat Y: **Prevalence of patent foramen ovale in patients with stroke.** *N Engl J Med* 1988, **318**:1148-1152.
2. Steiner MM, Di Tullio MR, Rundek T, Gan R, Chen X, Liguori C, Brainin M, Homma S, Sacco RL: **Patent foramen ovale size and embolic brain imaging findings among patients with ischemic stroke.** *Stroke* 1998, **29**:944-948.
3. de Belder MA, Tourikis L, Leech G, Camm AJ: **Risk of patent foramen ovale for thromboembolic events in all age groups.** *Am J Cardiol* 1992, **69**:1316-1320.
4. Webster MW, Chancellor AM, Smith HJ, Swift DL, Sharpe DN, Bass NM, Glasgow GL: **Patent foramen ovale in young stroke patients.** *Lancet* 1988, **2**:11-12.
5. Landzberg MJ, Khairy P: **Indications for the closure of patent foramen ovale.** *Heart* 2004, **90**:219-224.
6. Overell JR, Bone I, Lees KR: **Interatrial septal anomalies and stroke: a meta-analysis of case-control studies.** *Neurology* 2000, **55**:1172-1179.
7. Mas JL, Arquizan C, Lamy C, Zuber M, Cabanes L, Derumeaux G, Coste J: **Recurrent cerebrovascular events associated with patent foramen ovale, atrial septal aneurysm, or both.** *N Engl J Med* 2001, **345**:1740-1746.
8. Mas JL, Zuber M, French Study Group on Patent Foramen ovale and Atrial Septal Aneurysm: **Recurrent cerebrovascular events in patients with patent foramen ovale, atrial septal aneurysm, or both and cryptogenic stroke or transient ischemic attack.** *Am Heart J* 1995, **130**:1083-1088.
9. Meier B, Lock JE: **Contemporary management of patent foramen ovale.** *Circulation* 2003, **107**:5-9.
10. Stone DA, Godard J, Correti M, Kittner SJ, Sample C, Price TR, Plotnick GD: **Patent foramen ovale: association between the degree of shunt by contrast transesophageal echocardiogra-**

- phy and the risk of future ischemic neurologic events. *Am Heart J* 1996, **131**:158-161.
11. Homma S, Di Tullio MR, Sacco RL, Mihalatos D, Li Mandri G, Mohr JP: **Characteristics of patent foramen ovale associated with cryptogenic stroke: a biplane transesophageal echocardiographic study.** *Stroke* 1994, **25**:582-586.
 12. Brandt R, Neumann T, Neuzner J, Rau M, Faude I, Hamm CW: **Transcatheter closure of atrial septal defect and patent foramen ovale in adult patients using the Amplatzer occlusion device: no evidence for thrombus deposition with antiplatelet agents.** *J Am Soc Echocardiogr* 2002, **15**:1094-1098.
 13. Sharafuddin MJ, Gu X, Titus JL, Urness M, Cervera-Ceballos JJ, Amplatz K: **Transvenous closure of secundum atrial septal defects: preliminary results with a new self-expanding nitinol prosthesis in a swine model.** *Circulation* 1997, **95**:2162-2168.
 14. Bridges ND, Hellenbrand W, Latson L, Filiano J, Newburger JW, Lock JE: **Transcatheter closure of patent foramen ovale after presumed paradoxical embolism.** *Circulation* 1992, **86**:1902-1908.
 15. Sievert H, Babic UU, Hausdorf G, Schneider M, Höpp HW, Pfeiffer D, Pfisterer M, Friedli B, Urban P, on behalf of the ASDOS study group: **Transcatheter closure of atrial septal defect and patent foramen ovale with the ASDOS device (a multi-institutional European trial).** *Am J Cardiol* 1998, **82**:1405-1413.
 16. Braun M, Glied V, Boscheri A, Schoen S, Gahn G, Reichmann H, Haass M, Schraeder R, Strasser RH: **Transcatheter closure of patent foramen ovale (PFO) in patients with paradoxical embolisation.** *Eur Heart J* 2004, **25**:424-430.
 17. Mathewson JW, Bichel D, Rothman A, Ing FF: **Absent posteroinferior and anterosuperior atrial septal defect rims: factors affecting nonsurgical closure of large secundum defects using the Amplatzer occluder.** *J Am Soc Echocardiogr* 2004, **17**:62-69.
 18. Khairy P, Landzberg MJ: **Systematic review and analysis of transcatheter closure versus medical therapy for patent foramen ovale.** *Circulation* 2003, **107**:e175.
 19. Bruch L, Parsi A, Grad MO, Rux S, Burmeister T, Krebs H, Kleber FX: **Transcatheter closure of interatrial communications for secondary prevention of paradoxical embolism.** *Circulation* 2002, **105**:2845-2851.
 20. Dearani JA, Ugurlu BS, Danielson GK, Daly RC, McGregor CG, Mulany CJ, Puga FJ, Orszulak TA, Anderson BJ, Brown RD, Schaff HV: **Surgical patent foramen ovale closure for prevention of paradoxical embolism-related cerebrovascular ischemic events.** *Circulation* 1999, **100**(9 Suppl):II-171-5.
 21. Homma S, Di Tullio MR, Sacco RL, Sciacca RR, Smith C, Mohr JP: **Surgical closure of patent foramen ovale in cryptogenic stroke patients.** *Stroke* 1997, **28**:2376-2381.
 22. Adams H: **Patent Foramen Ovale. Paradoxical Embolism and Paradoxical Data.** *Mayo Clinic proceedings* 2004, **79**(1):15-20.
 23. Windecker S, Wahl A, Chatterjee T, Garachemani A, Eberli RF, Seiler C, Meier B: **Percutaneous closure of patent foramen ovale in patients with paradoxical embolism: long-term risk of recurrent thromboembolic events.** *Circulation* 2000, **101**:893-898.
 24. Köhler F, Glied V, Bohm J, Konertz W, Baumann G: **Interventioneller Verschluss von Vorhofseptumdefekten mit dem System ASDOS Kasuistische Erfahrungen zu Diagnostik und Management von Spätkomplikationen.** *Intensiv- und Notfallmedizin* 1997, **34**:401-408.
 25. Miller DL, Balter S, Cole PE, Lu HT, Berenstein A, Albert R, Schueler BA, Georgia JD, Noonan PT, Russell EJ, Malisch TW, Vogelzang RL, Geisinger M, Cardella JF, George JS, Miller GL 3rd, Anderson J: **Radiation doses in interventional radiology procedures: the RAD-IR study: part II: skin dose.** *J Vasc Interv Radiol* 2003, **14**(8):977-90.
 26. Picano E: **Sustainability of medical imaging.** *BMJ* 2004, **328**(7439):578-80.
 27. Bartel T, Konorza T, Arjumand J, Ebradlidze T, Eggebrecht H, Caspari G, Neudorf U, Erbel R: **Intracardiac echocardiography is superior to conventional monitoring for guiding device closure of interatrial communications.** *Circulation* 2003, **107**(6):795-7.
 28. Ewert P, Abdul-Khaliq H, Peters B, Schubert S, Nagdyman N, Lange PE: **Interventioneller Verschluss von Vorhofdefekten unter alleiniger Ultraschallkontrolle ohne Durchleuchtung.** *Poster Z Kardiol* 2004, **93**(3):325. Supplement
 29. Espinola-Zavaleta N, Munoz-Castellanos L, Attié F, Hernández-Morales G, Zamora-González C, Duenas-Carbajal R, Granados N, Keirns C, Vargas-Barrón J: **Anatomic three-dimensional echocardiographic correlation of bicuspid aortic valve.** *J Am Soc Echocardiogr* 2003, **16**:46-53.
 30. Acar P, Dulac Y, Roux D, Rougé P, Duterque D, Aggoun Y: **Comparison of transthoracic and transesophageal three-dimensional echocardiography for assessment of atrial septal defect diameter in children.** *Am J Cardiol* 2003, **91**:500-502.
 31. Acar P, Saliba Z, Bonhoeffer P, Aggoun Y, Bonnet D, Sidi D, Kachaner J: **Influence of atrial septal defect anatomy in patient selection and assessment of closure by the CardioSeal device: a three-dimensional transesophageal echocardiography study.** *Eur Heart J* 2000, **21**:573-581.
 32. Maeno YV, Benson IN, McLaughlin PR, Boutin C: **Dynamic morphology of the secundum atrial septal defect evaluated by three dimensional transesophageal echocardiography.** *Heart* 2000, **83**:673-677.
 33. Lange A, Walayat M, Turnbull CM, Palka P, Mankad P, Sutherland GR, Godman MJ: **Assessment of atrial septal defect morphology by transthoracic three dimensional echocardiography using standard gray scale and Doppler myocardial imaging techniques: comparison with magnetic resonance imaging and intraoperative findings.** *Heart* 1997, **78**:382-389.
 34. Espinola-Zavaleta N, Vargas-Barron J, Keirns C, Rivera G, Romero-Cardenas A, Roldan J, Attie F: **Three-dimensional echocardiography in congenital malformations of the mitral valve.** *J Am Soc Echocardiogr* 2002, **15**(5):468-72.
 35. Ahmed S, Nanda NC, Miller AP, Nekkanti R, Yousif AM, Pacifico AD, Kirklin JK, McGiffin DC: **Usefulness of transesophageal three-dimensional echocardiography in the identification of individual segment/scallop prolapse of the mitral valve.** *Echocardiography* 2003, **20**(2):203-9.
 36. Li J, Sanders SP: **Three-dimensional echocardiography in congenital heart disease.** *Curr Opin Cardiol* 1999, **14**(1):53-9.
 37. Gilon D, Cape EG, Handschumacher MD, Song JK, Solheim J, VanAuker M, King ME, Levine RA: **Effect of three-dimensional valve shape on the hemodynamics of aortic stenosis: three-dimensional echocardiographic stereolithography and patient studies.** *J Am Coll Cardiol* 2002, **40**(8):1479-86.

Publish with **BioMed Central** and every scientist can read your work free of charge

"BioMed Central will be the most significant development for disseminating the results of biomedical research in our lifetime."

Sir Paul Nurse, Cancer Research UK

Your research papers will be:

- available free of charge to the entire biomedical community
- peer reviewed and published immediately upon acceptance
- cited in PubMed and archived on PubMed Central
- yours — you keep the copyright

Submit your manuscript here:
http://www.biomedcentral.com/info/publishing_adv.asp

